

## SPINECOR: a New Therapeutic Approach for Idiopathic Scoliosis

C. COILLARD, M.A. LEROUX, J. BADEAUX, C.H. RIVARD

*Research Center, Sainte Justine Hospital, 3175 Côte Ste Catherine, Montréal, Canada*

Spinecor is the first brace of its generation linked to a new approach of idiopathic scoliosis treatment. Its principle is based on a better knowledge of the dynamics of the spine and of growth phenomena, resulting in the use of dynamic forces instead of static ones as the three points pressure that is commonly used for most of rigid braces.

The follow up at the end of the treatment for the first 55 patients treated by this brace now enables us to establish a first evaluation of the principle and its application. After an average of 20 months treatment duration and 21 months after the end of the treatment, we note that more than 87% patients have a real correction or are stabilized in their Cobb angle, thus avoiding surgery.

Results also show that the reducibility of the curves in the brace at the beginning of the treatment constitute an overall interesting prognosis parameter but which is hard to apply individually. Other factors must obviously be taken into account such as the impact of growth velocity on spinal deformation, at the beginning of adolescent growth spurt as well as structural deformities of the apex vertebrae when the diagnosis is made.

Brace treatment of idiopathic scoliosis has been alternately considered as a therapeutic panacea, excessive and disappointing, for eventually taking a better place in the proposed therapeutics. Nevertheless, compliance to brace treatment usually proposed is disappointing and often compromises its therapeutic effectiveness. Otherwise, the need for physical activity of a child or the self image awareness of an adolescent make the full acceptance of a rigid brace very uncertain. Finally, despite a better knowledge of spinal biomechanics, of growth and maturation phenomena and of a more realistic aetiopathogenic approach of idiopathic scoliosis, no major therapeutic impact has materialized for several years. For all these reasons, it seemed important to us, right from the early 1990's, to increase our knowledge about scoliotic pathology with the aim to improve the quality of the treatments proposed as well as the living conditions of the treated child and by the way his relatives. First, we attempted to the practical application of the new concept resulting from our studies to non surgical treatment of idiopathic scoliosis.

Among other things, it appeared obvious to us that the main requirement for a brace to be effective was to enable a sufficient curve reducibility, and even remove its potential aggravation that is very closely linked to spinal growth potential and to the severity of biomechanical disruptions as much static as dynamic.

Moreover, in order to avoid the disadvantages of a rigid brace that uses quite important static forces, we had, for the same result, to use dynamic forces less important but adjustable in time to interact with the variations in spinal flexibility due to the application of these forces. Today, we can not pretend to a definitely conclusive experience

but which is enough to confirm the therapeutic effectiveness of this innovatory approach. The short term effect is obvious and post treatment results of the first 55 patients confirm that this approach is valid.

This study concerns the first 55 patients with idiopathic scoliosis treated with Spinecor. The mean age at the beginning of the treatment was 13.1 (from 9.7 to 16.5 years old), for 53 girls and 2 boys. 12 of them had thoracic curves, 21 thoraco lumbar, 7 lombar and 15 double curves. Risser sign at the beginning of the treatment was 0 for 52.7%, 1 for 14.5%, 2 for 14.5% and 3 for 18.2%. Therapeutic indication is based on at least a 5° demonstrated progression of Cobb angle especially for curves less than 30° or the more mature patients : Risser 2 or 3, 12 years old or more. The indication is made without delay when risk is high supposed : Cobb angle superior to 30°, immature patient (Risser 0, less than 11 years old), high growth potential, close relatives operated for severe idiopathic scoliosis, major postural deformation with gibbosity superior to 7° (scoliometer measurement). Initial or pre therapeutic Cobb angle is mean 29°.

The brace used is the Dynamic Correction Brace (or Spinecor). It is a flexible harness that has been made and perfected at Hospital Ste Justine during the first three years of 1990. It is composed of a pelvic basis ( a low girdle including 3 soft thermomalleable parts) which is stabilized by 2 thigh bandages and 2 crotch bandages, a cotton bolero and 4 correcting elastic bandages of different sizes (from 20cm to 1m) (fig.1).

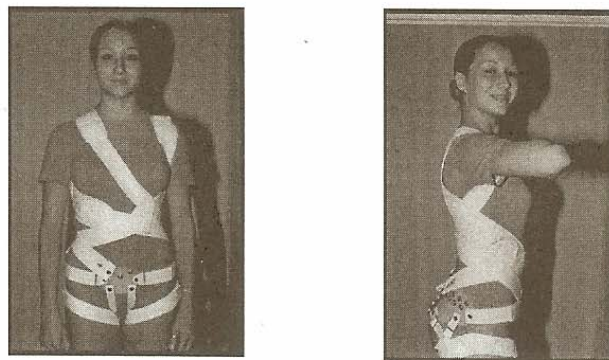


Fig.1

The therapeutic principle is based on the definition of a specific correcting movement for each kind of curve. The correcting movement made by this brace (or harness) produces a progressive positional change and contributes to the dynamic correction of the curves during daily activity and sport practice of the child. The objective is to enable a non aggressive progressive reduction, without hindering growth proceeding of skeletal structures while favouring the acquisition of a more appropriate muscular balance. The required daily wearing duration is 20 hours on 24 during rapid growth periods and from 10 to 12 diurnal hours during slow growth periods. Brace wearing is stopped close to skeletal maturity, that is to say Risser 4 or 5, and/or after two years of regular menstruation.

Post treatment results are estimated from radiographies made 21 months on average after total ending of the treatment (6 months minimum, 54 months maximum) compared to immediate pre therapeutic radiography. We can note that:

- 22 patients had 42% mean correction (11°), mean initial Cobb angle : 29°,
- 26 remained stable with 8% mean difference (2°), mean initial angle : 27°,



- 7 had 52% mean aggravation (15°), mean initial angle : 30°; but surgery was not necessary,
- 3 required surgery after 73% mean aggravation (23°), 2 double curves and 1 thoraco lumbar curve.

Out of the 22 patients who had their Cobb angle corrected, 36% had more than 50% correction with a minimum of 14 months follow-up, 50% had a correction between 20 and 50%, and 14% had a correction of less than 20%.

The results obtained with this first series of patients are very encouraging. Taken as a whole, the success rate is more than 87% and thus very satisfying for this non aggressive innovatory therapeutic approach. But even more we still remain surprised by the quality of postural and cosmetic results obtained as well as by the compliance to treatment showed by most of the patients.

Moreover, this study shows us that it is important, for a better understanding of the results, to consider on one hand, the influence of growth velocity on the evolution of braced curves and on the other hand, the importance of vertebral deformations at the time of diagnosis.